



AFRICAN ALTERNATIVE PRACTICES FOR EYE DISEASES

TEXT

A LITTLE BACKGROUND...

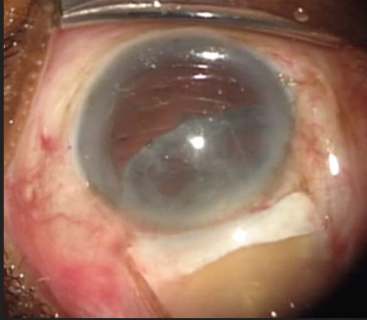
- ▶ No financial disclosures.
- ▶ Have worked at Tenwek Mission Hospital since 2006 with 3 intervening furloughs in Birmingham, AL with Retina Consultants of Alabama

Keep it Simple



AFRICAN ALTERNATIVE TREATMENTS

MANUAL SMALL INCISION CATARACT SURGERY (MSICS)



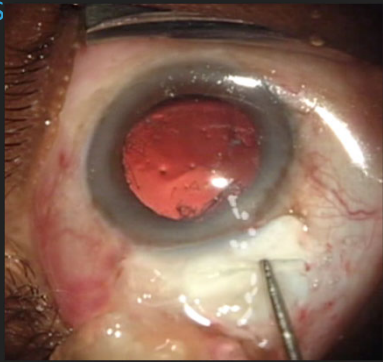
AFRICAN ALTERNATIVE TREATMENTS

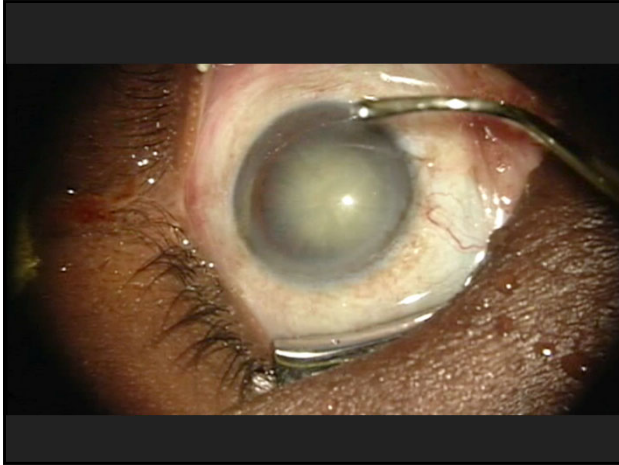
MANUAL SMALL INCISION CATARACT SURGERY (MSICS)

- ▶ The preferred surgical technique for the developing world.
- ▶ Affordable, reproducible, efficient.

QUALITY M.S.I.C.S

- ▶ Patient selection
- ▶ Wound construction
- ▶ Capsulorhexis options
- ▶ Nucleus delivery
- ▶ IOL placement

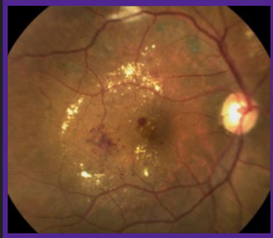




AFRICAN ALTERNATIVE TREATMENTS

DIABETIC MACULAR EDEMA

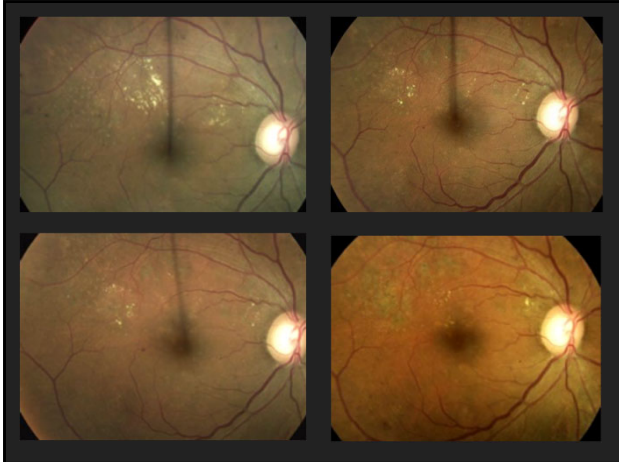
- ▶ Protocol I and T:
 - ▶ Intravitreal anti-VEGF injections superior to traditional focal laser for central involving DME.
- ▶ Costs in Kenya
 - ▶ Bevacizumab - \$55
 - ▶ Ranibizumab - \$350
 - ▶ Aflibercept - \$400



AFRICAN ALTERNATIVE TREATMENTS

DIABETIC MACULAR EDEMA

- ▶ Tenwek protocol...
 - ▶ Initial intravitreal anti-VEGF treatment (Avastin)
 - ▶ Followed by focal/grid laser one month later



AFRICAN ALTERNATIVE TREATMENTS

DIABETIC MACULAR EDEMA


- ▶ Laser still works!
- ▶ Can be combined with anti-VEGF for effective treatment in resource limited environments.



AFRICAN ALTERNATIVE TREATMENTS

UVEITIS WORK UP AND TREATMENT

- ▶ Etiologies for uveitis can be broad.



AFRICAN ALTERNATIVE TREATMENTS

UVEITIS WORK-UP AND TREATMENT

- ▶ Location of inflammation
 - ▶ **Anterior**- pain, redness, photophobia
HLA B-27, RPR, FTA-Abs,
 - ▶ **Intermediate**- anterior inflammation with deeper pain
CXR, Lyme Ab, ?ACE, lysozyme
 - ▶ **Posterior**- Floaters, visual disturbances in absence of pain
MRI (MS),
 - ▶ **Panuveitis**- pain with inflammation in all areas of eye.
Toxoplasmosis IgG, IgM, Quantum Gold, HLA testing, PCR testing

AFRICAN ALTERNATIVE TREATMENTS

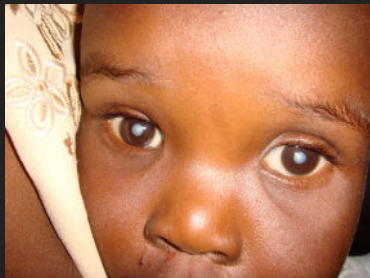UVEITIS WORK-UP AND TREATMENT WITH RESOURCE LIMITATIONS

- ▶ Targeted history
- ▶ Key question: **Is this infectious or not?**
- ▶ Limited work up: ESR, VDRL, HIV, CXR, ?Gene Xpert for TB
 - ▶ If infectious, identify and treat the infection.
 - ▶ If not infectious, treat with steroids.
 - ▶ Prednisolone acetate 1%, Oral prednisone,
 - ▶ Methotrexate

AFRICAN ALTERNATIVE TREATMENTS

PEDIATRIC CATARACT

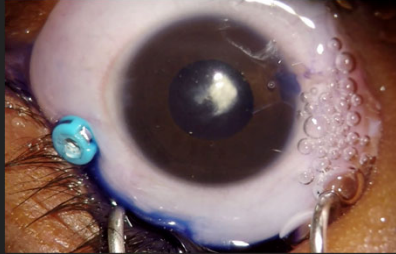
- ▶ Causes:
 - ▶ **Inherited**
 - ▶ Infections
 - ▶ Metabolic
 - ▶ **Trauma**
 - ▶ Drug reactions



AFRICAN ALTERNATIVE TREATMENTS

PEDIATRIC CATARACT

- ▶ Clear cornea approach
- ▶ Continuous capsulorhexis
- ▶ Primary posterior capsulotomy



AFRICAN ALTERNATIVE TREATMENTS

PEDIATRIC CATARACT

- ▶ Standard IOL choice
 - ▶ If less than 1 year old, often left aphakic. Correction is done with contact lens or aphakic specs.
 - ▶ If older than 1 year, patient is frequently left hyperopic as to aim towards emmetropia as a teen.

AFRICAN ALTERNATIVE TREATMENTS


TENWEK PEDIATRIC CATARACT PROTOCOL

- ▶ If bilateral cataracts, then do **both** surgeries consecutively in the same anesthetic setting.
- ▶ Do primary posterior capsulotomy using vitrector through trochar cannula
- ▶ Never leave aphakic if possible. Contact lenses are not an option.
- ▶ Consider patient's social situation and ability to follow up when choosing IOL power.

AFRICAN ALTERNATIVE TREATMENTS

ALLERGIC CONJUNCTIVITIS

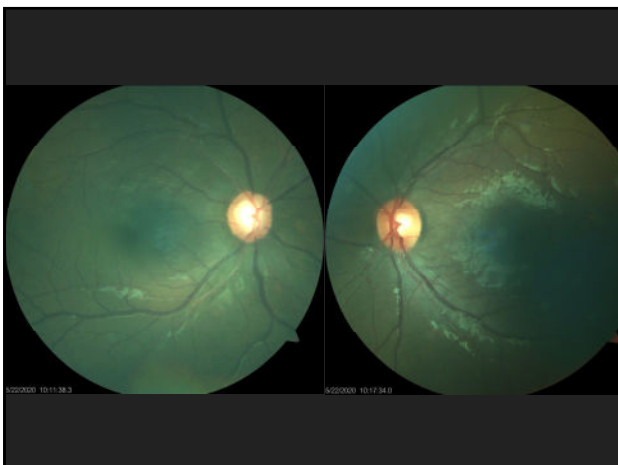
▶ Very common in equatorial Africa.



AFRICAN ALTERNATIVE TREATMENT

ALLERGIC CONJUNCTIVITIS TREATMENT

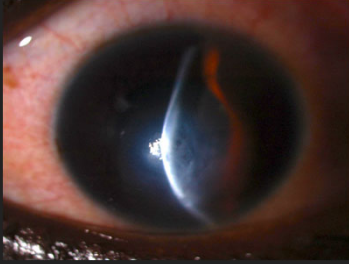
- ▶ Mast cell stabilizer/antihistamine (Olopatadine, Cromolyn)
- ▶ Lubricating tear drops
- ▶ Topical steroids
- ▶ Supratarsal triamcinolone
- ▶ Oral antihistamine (Cetirizine)
- ▶ Extreme cases...superficial keratectomy



AFRICAN ALTERNATIVE TREATMENTS

CROSS-LINKING FOR KERATOCONUS

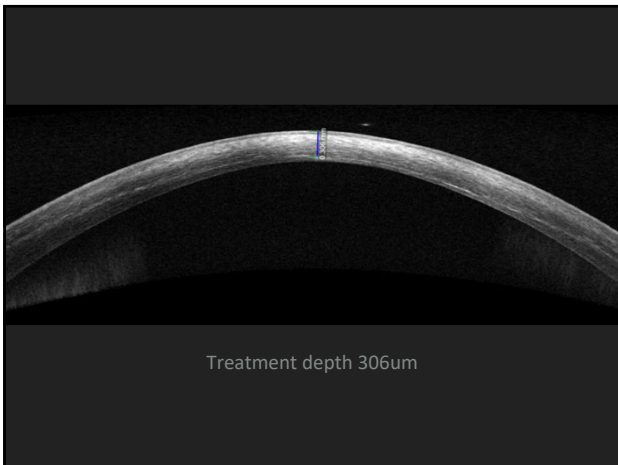
- ▶ KCN is very common in Kenya secondary to severe allergies (mostly vernal) and eye rubbing



AFRICAN ALTERNATIVE TREATMENTS

CROSS-LINKING FOR KERATOCONUS - TENWEK PROTOCOL

- ▶ Demonstrate progression of KCN if possible.
- ▶ Treating corneas as thin as 360um (with hypotonic Riboflavin)
- ▶ Remove epithelium; Use Riboflavin, either isotonic or hypotonic, dropping q 1-2 minutes for 30 minutes
- ▶ UV light (10mW) for 9 minutes



AFRICAN ALTERNATIVE TREATMENTS

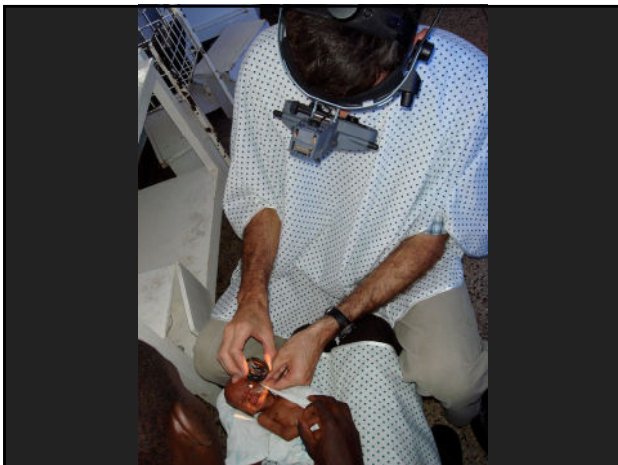
WHY TREAT CORNEAS THIS THIN?

- ▶ All of these advanced KCN patients will progress to needing PK/DALK without halting progression of disease.
- ▶ Tissue is very limited...only what is donated from the west.
- ▶ PK failure rate is much higher in children!

AFRICAN ALTERNATIVE TREATMENTS

ROP IN AFRICA

- ▶ Incidence is lower because survival of premature babies is lower.
- ▶ Tenwek Screening protocol: <1500gm at birth; alive 4 wks
- ▶ 2006-2016 Tenwek NICU 12-15 babies treated/year
- ▶ 2017-2020 Tenwek NICU 20-25 babies treated/year
- ▶ Why the increase?
 - ▶ Surfactant



AFRICAN ALTERNATIVE TREATMENTS

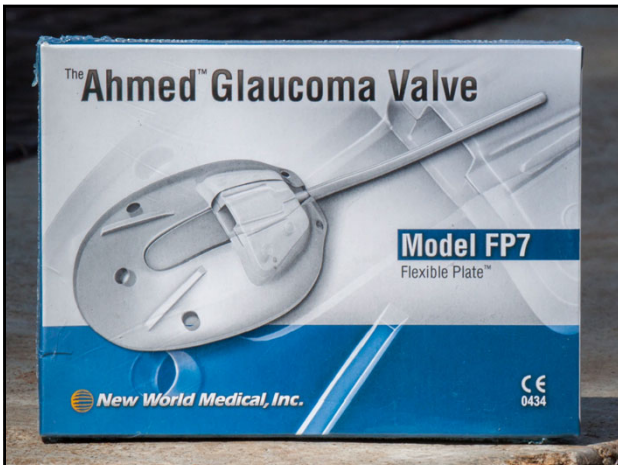
ROP TREATMENT AT TENWEK

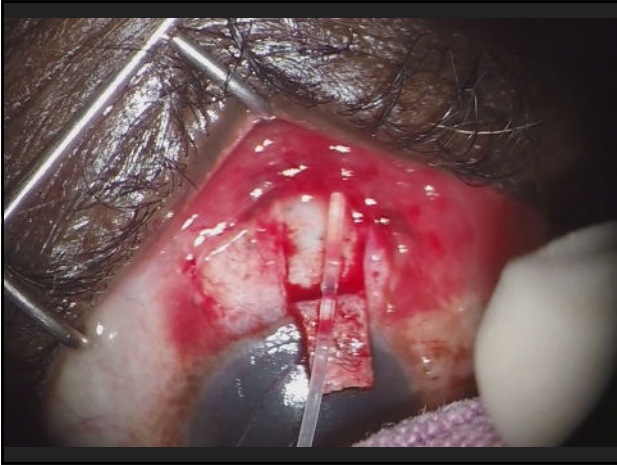
- ▶ Type 1 ROP
 - ▶ Stage 1+, 2+, 3, 3+ Zone I
 - ▶ Stage 2+, 3+ Zone II
- ▶ Until 2015- PRP laser performed under sedation.
- ▶ Since 2016- Avastin used for all type 1 ROP
 - ▶ 0.625mg (.025cc) Avastin
 - ▶ Retreatment rare
 - ▶ Performed at bedside with speculum and betadyne prep

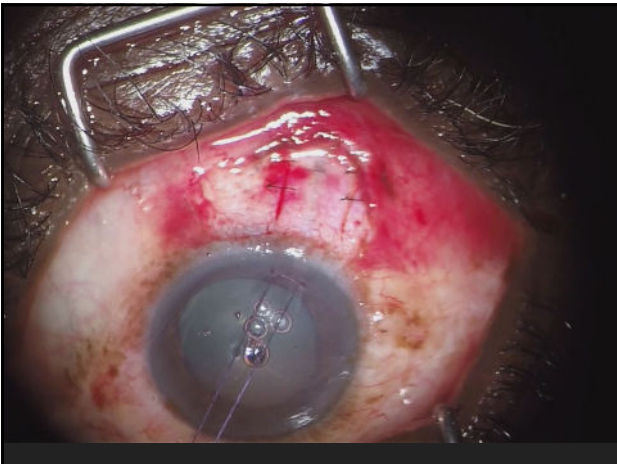
AFRICAN ALTERNATIVE TREATMENTS

GLAUCOMA TREATMENTS AT TENWEK

- ▶ Treatments:
 - ▶ Medical management
 - ▶ All drug classes available except Rho Kinase Inhibitors
 - ▶ Ciliary body destructive laser (Micropulse, G probe CPC)
 - ▶ Surgery: Trabeculectomy, Ahmed shunt
- ▶ Shunt tube technique







AFRICAN ALTERNATIVE TREATMENTS

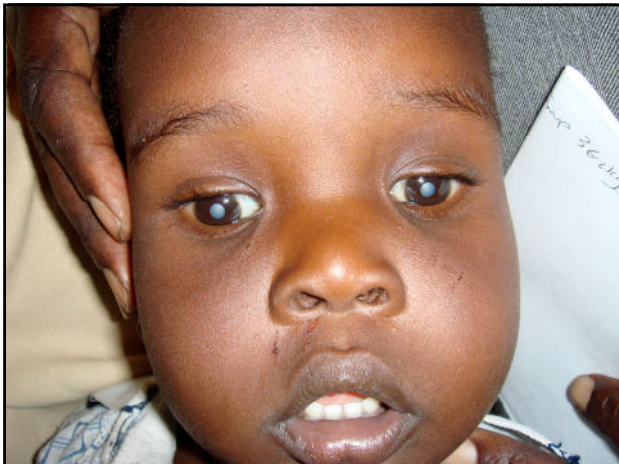
IMMEDIATE SEQUENTIAL BILATERAL EYE SURGERY (ISBES)

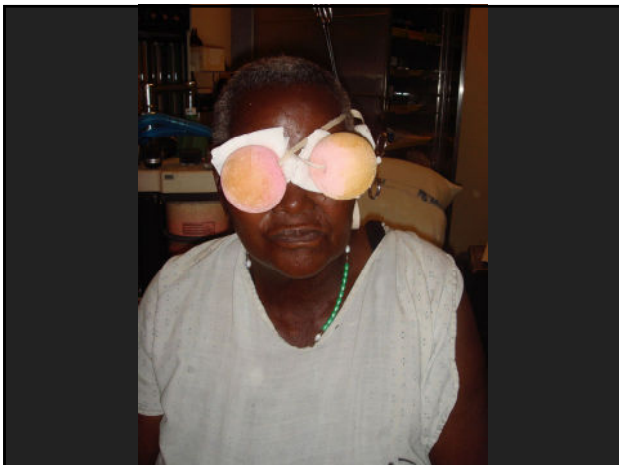
- ▶ Usually refers to bilateral cataract surgery, but can include others.
- ▶ Advantages:
 - ▶ Minimize repeated anesthetic risks.
 - ▶ Reduce follow up visits.
- ▶ Disadvantages:
 - ▶ Potential risks of bilateral endophthalmitis or cornea edema (endothelial dysfunction)
 - ▶ Anisometropia since 2nd eye IOL choice cannot be adjusted

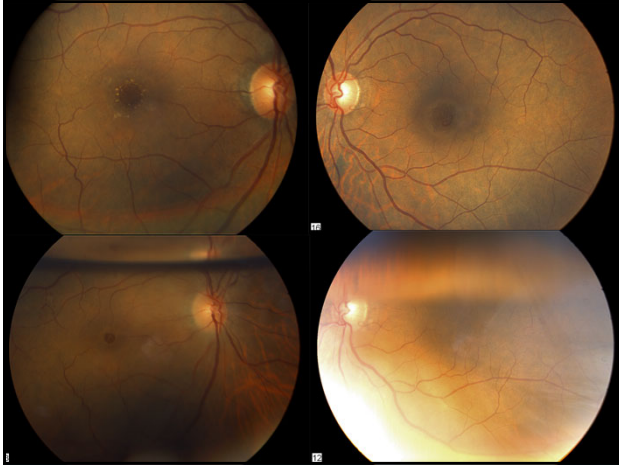
AFRICAN ALTERNATIVE TREATMENTS

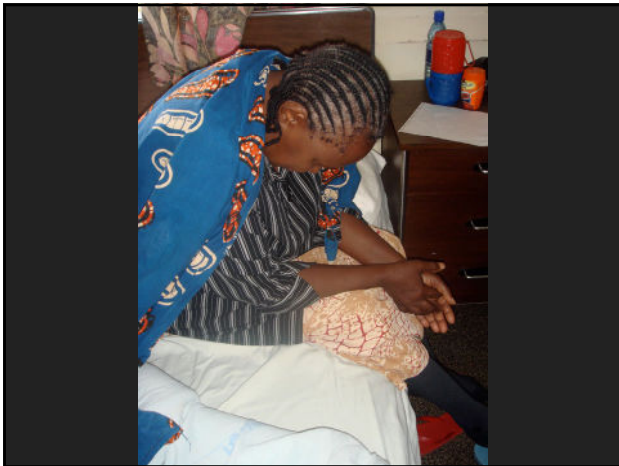ISBES - TENWEK PRACTICES

- ▶ Bilateral surgery done when continued follow-up is going to be a problem
- ▶ Pediatric cataract surgery, to minimize repeated anesthetic risks
- ▶ Bilateral macular hole surgery, to minimize face down positioning
- ▶ We mitigate risks of infection by changing drapes, surgical instruments, gloves, and by using intracameral antibiotics









AFRICAN ALTERNATIVE TREATMENTS

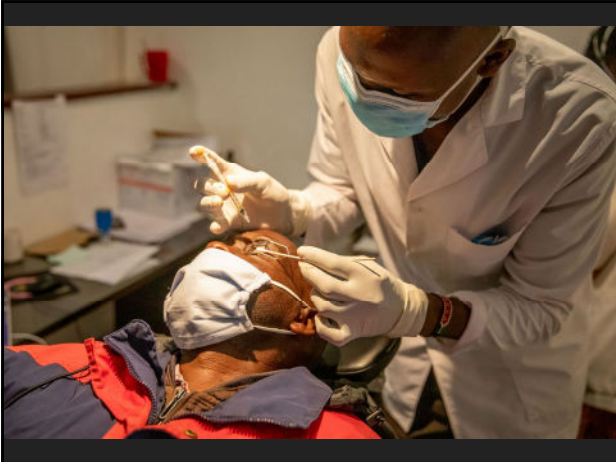
NURSE ADMINISTERED INTRAVITREAL INJECTIONS

ARVO Annual Meeting Abstract | June 2015

Nurse-administered intravitreal injections: a systematic review

Emily Li; Paul B Greenberg; Magdalena G Krzystolik

- ▶ Location of studies reviewed was UK
- ▶ Rates of endophthalmitis similar to physician injections (<.1%)
- ▶ Patient satisfaction with decreased wait time.
- ▶ Greater access to retina specialist for other problems



AFRICAN ALTERNATIVE TREATMENTS

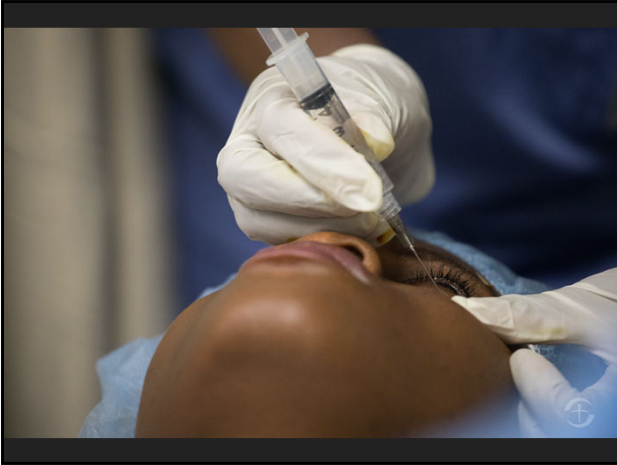NURSE ADMINISTERED INTRAVITREAL INJECTIONS - AT TENWEK

- ▶ Only nurses trained by physician or head injection nurse can participate.
- ▶ Physician is always immediately available if there is a concern before/after injection, or if patient requests a physician.
- ▶ No increase in complications

AFRICAN ALTERNATIVE TREATMENTS

ANESTHESIA FOR EYE SURGERY

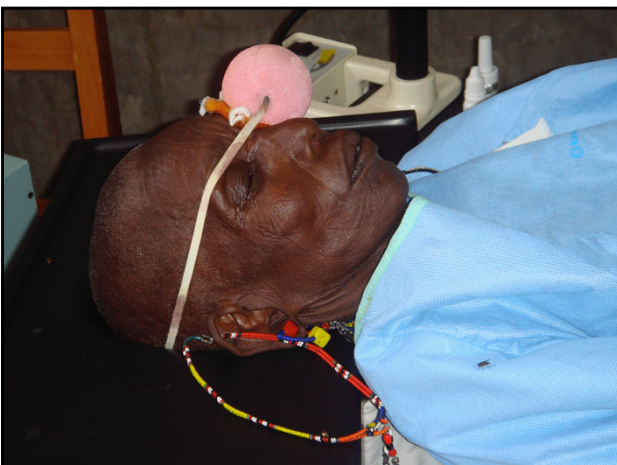- ▶ Topical (and intracameral)- safest for elective cataract surgery
- ▶ Peribulbar- often used for retina surgery
- ▶ Retrobulbar- often used for retina surgery
- ▶ Modified General anesthesia
- ▶ General anesthesia- common for pediatric surgeries and ruptured globe repairs



AFRICAN ALTERNATIVE TREATMENTS

TENWEK PROTOCOL

- ▶ Retrobulbar for most elective eye surgery
 - ▶ preferred when there is a language barrier
 - ▶ eliminates pain and motility during surgery
 - ▶ provides extended pain control
 - ▶ preferred for training cases where procedures take longer



AFRICAN ALTERNATIVE TREATMENTS

TENWEK PROTOCOL

- ▶ Majority of RB injections are given by trained **nurses**
 - ▶ highly experienced, high volume
 - ▶ Enables for more efficient operating room
 - ▶ understand potential complications
 - ▶ globe penetration
 - ▶ respiratory depression

AFRICAN ALTERNATIVE TREATMENTS

TENWEK PROTOCOL

- ▶ Retrobulbar blocks are used *even* in ruptured globe cases.
 - ▶ Block and procedure is carefully explained to patient
 - ▶ Volume of block is carefully titrated
 - ▶ Honan "super pinky" ball is NOT used.
 - ▶ Eliminates need for general anesthesia

AFRICAN ALTERNATIVE TREATMENTS

DEMENTIA AND CATAR



AFRICAN ALTERNATIVE TREATMENTS

DEMENTIA AND CATARACTS

Br J Ophthalmol. Author manuscript; available in PMC 2014 Aug 4. PMID: PMC4119932
Published in final edited form as: EMSID: EMS59815
Br J Ophthalmol. 2011 Jan; 95(1): 17-23. PMID: 20807709
Published online 2010 Aug 31. doi: 10.1136/bjo.2009.165902

Cataract and Cognitive Impairment: A Review of the Literature


Joanna M. Jefferis,^{1,2} Urs P. Mosimann,² and Michael P. Clarke^{1,3}

- ▶ “Visual impairment due to cataract may stress impaired intentional mechanisms, and cataract extraction may improve cognitive performance in some patients with early cognitive impairment.”


AFRICAN ALTERNATIVE TREATMENTS

DEMENTIA AND CATARACTS

- ▶ Dementia and cataracts are both age related.
- ▶ Confusion is amplified by blindness and unfamiliar environment



Post-op day #1 after patch removal



AFRICAN ALTERNATIVE TREATMENTS

SUMMARY

- ▶ The practice of evidenced based medicine is critical, even in the global setting.
- ▶ But sometimes alternative techniques and protocols have to be established because of limited resources.