

Retina Panel

SEC 2024



CASES

A STANDS FOR AGE IN AMD

WHO CARES ABOUT A LITTLE SWELLING, I NEED CATARACT SURGERY!

CATARACT SURGERY WENT FINE BUT MY RETINA IS INCHED AND SOMETHING FELL TO THE BACK OF THE EYE

CATARACT SURGERY WENT FINE, BUT NOW I CAN'T SEE

SURGERY?... BUT I HAVE TO GO TO MEGAS!


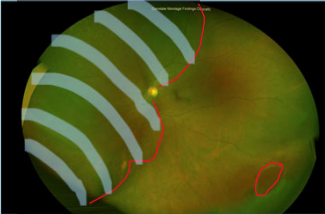
WHO CARES ABOUT A LITTLE DISTORTION, I NEED CATARACT SURGERY?


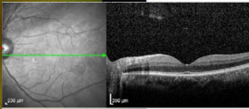
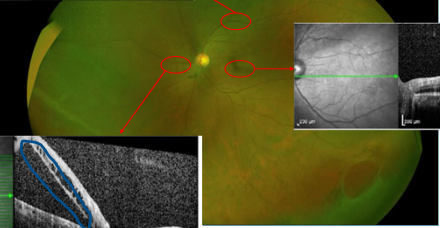
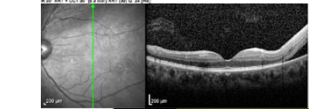
I SAW A COMMERCIAL THAT SAID YOU CAN FIX MY AMD

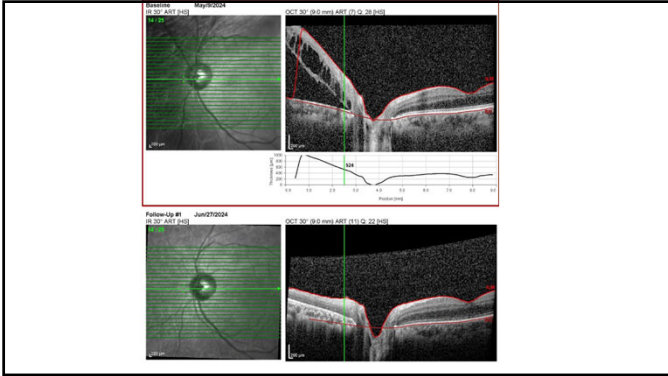
RD EVALUATION

- Audience: Expectations?
- Panel:
 - Timing?
 - Counseling?
 - Expectations?
 - What do you send back?
 - If phakic, how soon can they have CE/IOL after repair?

48-year-old female referred for an asymptomatic retinal detachment.







> [Ophthalmol Retina](#). 2023 Mar;7(3):215-220. doi: 10.1016/j.oret.2022.09.004. Epub 2022 Sep 24.

Asymptomatic Rhegmatogenous Retinal Detachments: Outcomes in Patients without Initial Surgical Intervention

Jesse D Sengillo ¹, William E Smiddy ¹, Benjamin Lin ¹, Marissa K Shoji ¹, Justin Townsend ¹, Nicolas A Vanzanuzzi ¹, Harry W Flynn Jr ²

Affiliations: [+ expand](#)
 PMID: 36162748 DOI: 10.1016/j.oret.2022.09.004
[Free article](#)

- The study group included 18 patients (20 eyes).
- The mean follow-up duration was 5.1 years (range, 0-30 years).
- During the follow-up, 2 (10%) patients exhibited progression of their asymptomatic RD and underwent surgical intervention.



AMD MIMICKERS

Audience:

- What makes you suspicious for AMD mimickers?
- Checking medications
- How do you screen pentosan polysulfate? Hydroxychloroquine patients?
- Do you have them stop their medications before referring?

Panel:

- Do you advise stopping with ANY macular pathology?

55-year-old female coming in for evaluation for AMD

Journal of Ophthalmology, 2019; Nov; 15(11):1783-1802. doi: 10.1096/jophta.2019.04.026. Epub 2019 May 22.

Pigmentary Maculopathy Associated with Chronic Exposure to Pentosan Polysulfate Sodium

William A Pearce¹, Rui Chen¹, Nanyang Jiao²

Affiliation: ¹retinal

PMID: 30807889. DOI: 10.1016/j.ophta.2019.04.026

J Clin Ophthalmol. 2021 Apr; 85(4):516-520. doi: 10.1096/jco.2020.03.001. Epub 2020 Jan 20.

Pentosan-associated maculopathy: prevalence, screening guidelines, and spectrum of findings based on prospective multimodal analysis

Shirish Mehra¹, Adnan Ali¹, Frederic Dumoulin¹, Anur Holey¹, Jackson Schmitt¹, David Tran¹, Michael Kim¹, Jay Meng Chen¹, David Wong¹

Affiliation: ¹retinal

PMID: 32873791. DOI: 10.1016/j.jco.2020.03.001

Recommendations

- "We recommend an initial baseline eye examination to include OCT and, most importantly, NIR and FAF with **annual retinal imaging** thereafter especially with cumulative dosages approaching **500 g**. Patients exposed to greater than **1500 g** of PPS are at significant risk of retinal toxicity."
- Average dose of pentosen polysulfate is 300mg/day
- **1666 days patients or after ~4.5 years**

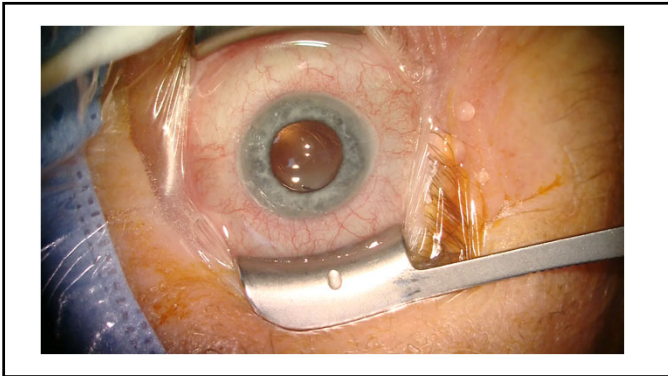


**Retained
Lens
Fragment
REFERAL**


Audience:
What are your practice patterns?
What do you want/expect your retina colleague to do?

Panel:
What determines your surgical plan?

- IOP/Cornea/Retinal Pathology
- Optimal timing for surgery
- Staged or combined secondary IOL
- What type of secondary IOL do you prefer
- What preoperative information is helpful (IOL calcs?)





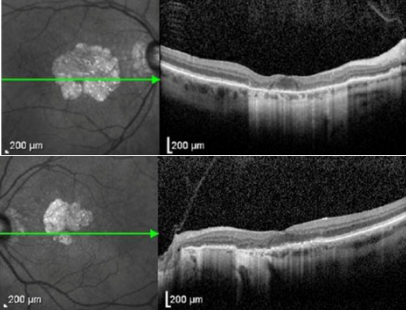


Dry AMD
Evaluation

For the audience: Who do you want to referred?

Panel: Counseling?

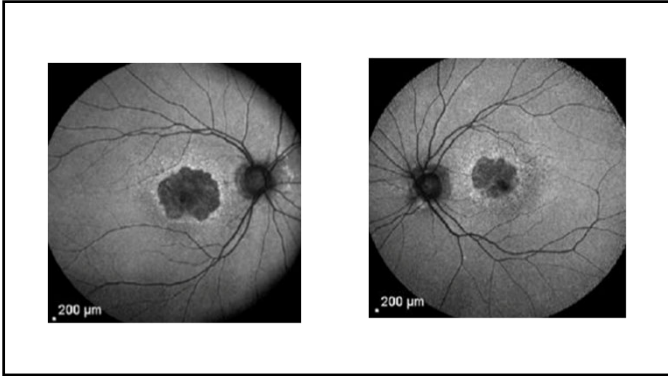
83-year-old male reporting worsening vision, most noticeably over 2 months



200 µm 200 µm

200 µm 200 µm

VA OD: Dcc20/60+2 PHNI
VA OS: Dcc20/40+2 PHNI
IOP: TP: OD:16 OS:14 Time:01:23 PM

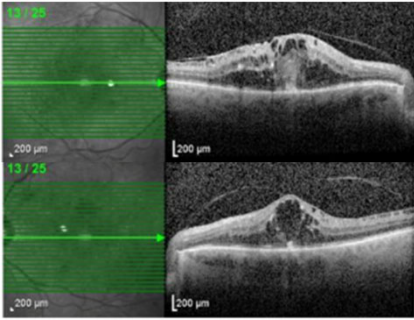


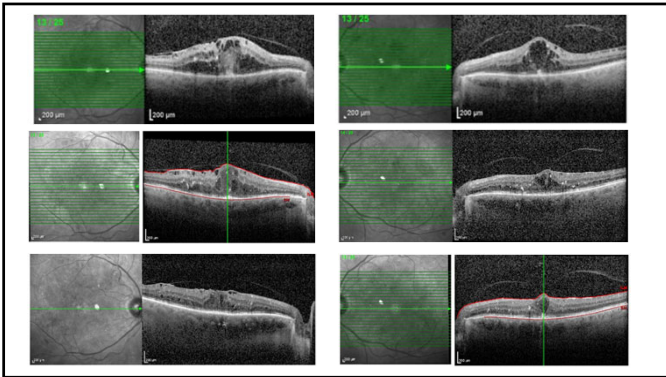


CATARACT SURGERY
CLEARANCE WITH
DIABETIC
RETINOPATHY

- Audience:
 - When and who do you send?
- Panel:
 - Considerations?
 - Edema versus PDR
 - Expectations
 - Timing?
- Can apply to wet AMD?
 - Timing of injections

52-year-old male referred for cataract surgery clearance with evidence of macular edema on OCT.





Studies
DRCR.net

- **Protocol P:** patients with NPDR but no history of DME were found to have a substantial risk of postoperative DME after cataract surgery.
- **Protocol Q:** (preexisting DME), only a small percentage of eyes had substantial visual acuity loss or definitive progression in central retinal thickening.
- Therefore, in clinical practice, it is common for patients with center-involved DME who are about to undergo cataract surgery to receive an anti-VEGF drug injection preoperatively or steroid injection perioperatively.



CATARACT SURGERY CLEARANCE WITH ERM?

- What other ocular conditions influence recommendation
 - POAG/AMD/macular hole/dystrophy
- Order of surgery?
- Counseling

• 62-year-old male with mild/moderate POAG and +2 NSC with visual distortion OS

The image displays four panels of ocular imaging. The top-left panel is a fundus photograph showing the retina with a green grid overlay. The top-right panel is an OCT scan showing a cross-section of the retina with a red line indicating the boundary of the optic nerve head. The bottom-left panel is another fundus photograph with a green grid. The bottom-right panel is another OCT scan showing a cross-section of the retina with a red line. Each panel includes a scale bar in the bottom-left corner.

Clin Oculthalmol. 2015; 9: 1999-2003. PMID: PMC4629981
 Published online 2015 Oct 23. doi: 10.2147/OPTH.S94948 PMID: 26504609

Efficacy of vitrectomy and epiretinal membrane peeling in eyes with dry age-related macular degeneration

John O Mason, Jit^{1,2} and Shyam A Patel¹

> J Vitreoretin Dis. 2024 Feb 22;8(3):247-252. doi: 10.1177/24741264241231091. eCollection 2024 May-Jun.

Long-Term Outcomes of Vitrectomy for Idiopathic Epiretinal Membrane With Internal Limiting Membrane Removal in Patients With Good Preoperative Visual Acuity

Sean C Drummond¹, Jason N Crosson², John O Mason 3rd²



MY CATARACT SURGERY WENT FINE, BUT NOT I CAN'T SEE

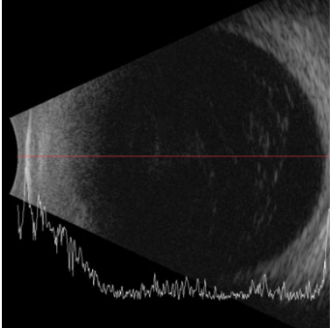
54-year-old male underwent mostly uneventful cataract surgery for a traumatic cataract.

Audience:
What do you do if your standard anterior capsular staining agent is out of stock?

54-year-old male underwent mostly uneventful cataract surgery for a traumatic cataract.

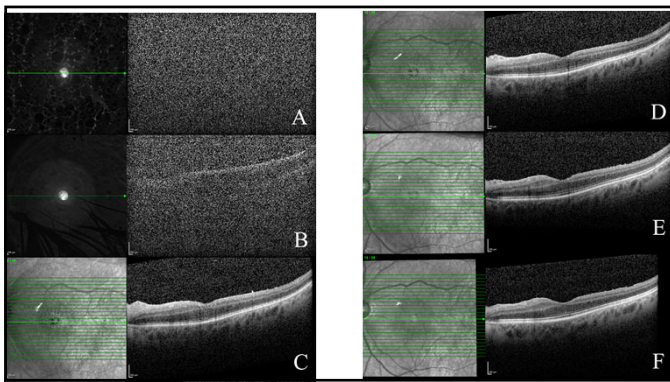
Trypan blue not available, so ICG used to stain anterior lens capsule

Noted to migrate to vitreous cavity during surgery, but able to successfully implant IOL.



POD1 CF VA, sent to retina clinic

PPV done next day



Case Reports > J Cataract Refract Surg. 2000 Nov;26(11):1691-3.
doi: 10.1016/s0886-3350(00)00432-6.

Indocyanine green staining in traumatic cataract

T H Newsome, T A Oetting

PMID: 11084282 DOI: 10.1016/s0886-3350(00)00432-6

Case Reports > J Cataract Refract Surg. 2006 Feb;32(2):357-60.
doi: 10.1016/j.jcrs.2005.12.038.

Retained posterior segment indocyanine green dye after phacoemulsification

Richard C Allen¹, Stephen R Russell, Mark L Schlotzer, Thomas A Oetting

Affiliations + expand
PMID: 16565018 DOI: 10.1016/j.jcrs.2005.12.038